

Images and Case Reports in Arrhythmia and Electrophysiology

Acute Liver Failure Associated With Dronedarone

Nader Joghetaei, MD; Gregor Weirich, MD; Wolfgang Huber, MD;
Peter Büchler, MD; Heidi Estner, MD

A 70-year-old woman was initially referred to a community hospital for progressive fatigue and hyperbilirubinemia for 2 weeks. Six months before admission, she was started on dronedarone for atrial fibrillation. The latest liver function tests had been within normal range 9 months before admission. Her medical history included coronary artery disease and chronic obstructive pulmonary disease. She had no allergies. She did not smoke, drink alcohol, or use illicit drugs. Her current medication included aspirin, bisoprolol, dronedarone, lisinopril, hydrochlorothiazide, amlodipine, formoterol, ipratropium bromide, and simvastatin. Over the course of her hospital stay, her total bilirubin peaked at 30.3 mg/dL, she had development of coagulopathy refractory to therapy (precluding liver biopsy), and serial ultrasound Doppler flow imaging of the liver showed reduced portal flow and beginning cirrhosis. She tested negative for Hepatitis A, B, and C viruses, hemochromatosis, and HIV. The rapid plasma reagin test, autoimmune panel, thyroid function, serum copper, and ceruloplasmin were all within normal limits. Acetaminophen blood tests were negative.

On the basis of the timing of jaundice in relation to dronedarone exposure and the absence of any other identifiable cause, she was diagnosed with dronedarone-induced acute liver failure. Liver function tests did not improve with high-dose steroid therapy. On the 9th day of admission, altered mental status and beginning of hepatic encephalopathy was noted.

She was therefore transferred to the university hospital for liver transplantation. Her clinical condition deteriorated with onset of grade 3 hepatic encephalopathy. Because her previous health condition was good, she was considered for high-urgency liver transplantation, which was performed on the 11th day of hospitalization. The operation was successful; she remained critically ill for the first postoperative week and recovered gradually but completely in the following 10 weeks.

Histopathology detected widespread necrosis of liver acini, massive canalicular and ductular cholestasis, a mixed cellular inflammatory infiltrate, and bile duct proliferation (Figure, B through D).

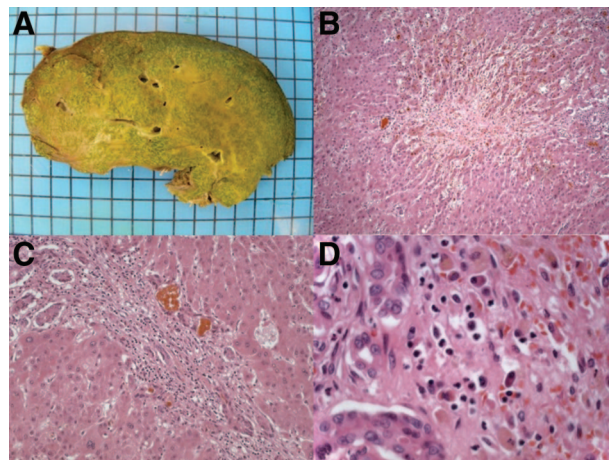


Figure. Gross and histopathologic characteristics of explanted liver. **A**, Gross examination revealed a cholestatic organ; **B**, histopathologic evaluation demonstrated widespread necrosis; **C**, canalicular and ductular cholestasis; and **D**, mixed pattern of inflammatory cells (see text).

Discussion

This case report and others led to the Safety Announcement of the US Food and Drug Administration about cases of rare but severe liver injury in patients treated with the heart medication dronedarone (Multaq) in January 2011.

Dronedarone was developed as a potent antiarrhythmic drug without the side effects of amiodarone for treatment of atrial fibrillation. Reports on hepatotoxic effects of dronedarone have been controversial: In the Athena trial,¹ abnormal liver function tests were reported in 12 of 2291 patients (0.5%), whereas in the Euridis/Adonis trials,² hepatic events occurred in 100 of 822 patients (12%).

Dronedarone is metabolized in the liver by cytochrome P450 3A4. Hepatotoxicity may be based on the same pathomechanism underlying the conformational structure of dronedarone and amiodarone. Amiodarone causes a broad spectrum of hepatic manifestations from benign increases in aminotransferase levels to fatal hepatitis and cirrhosis.³ One of the

Received March 9, 2011; accepted April 26, 2011.

From Deutsches Herzzentrum und I Medizinische Klinik, Klinikum rechts der Isar (N.J., H.E.); Institut für Allgemeine Pathologie und Pathologische Anatomie, Klinikum rechts der Isar (G.W.); II Medizinische Klinik und Poliklinik, Klinikum rechts der Isar (W.H.); and Munich Liver Transplant Centre, Klinikum rechts der Isar, Technische Universität München (P.B.), Munich, Germany.

Correspondence to Heidi Estner, MD, Deutsches Herzzentrum und I Medizinische Klinik, Klinikum rechts der Isar, Technische Universität München, Lazarettstr. 36, 80636 München, Germany. E-mail heidi@estner.org

(*Circ Arrhythm Electrophysiol.* 2011;4:592-593.)

© 2011 American Heart Association, Inc.

Circ Arrhythm Electrophysiol is available at <http://circep.ahajournals.org>

DOI: 10.1161/CIRCEP.111.963447

mechanisms for amiodarone-induced hepatotoxicity includes impairment of mitochondrial β -oxidation and uncoupling oxidative phosphorylation. This induces microsteatosis, apoptosis, and necrosis of hepatocytes.⁴

Our patient had normal liver function before dronedarone treatment, and the medication was taken for 6 months without monitoring the liver function tests in the meantime. On the basis of this case report, we propose that clinicians considering dronedarone therapy monitor liver function parameters as recommended now by the US Food and Drug Administration.

Disclosures

None.

References

1. Hohnloser SH, Crijns HJ, van Eickels M, Gaudin C, Page RL, Torp-Pedersen C, Connolly SJ. Effect of dronedarone on cardiovascular events in atrial fibrillation. *N Engl J Med.* 2009;360:668–678.
2. Singh BN, Connolly SJ, Crijns HJ, Roy D, Kowey PR, Capucci A, Radzik D, Aliot EM, Hohnloser SH. Dronedarone for maintenance of sinus rhythm in atrial fibrillation or flutter. *N Engl J Med.* 2007;357:987–999.
3. Mattar W, Juliar B, Gradus-Pizlo I, Kwo PY. Amiodarone hepatotoxicity in the context of the metabolic syndrome and right-sided heart failure. *J Gastrointest Liver Dis.* 2009;18:419–423.
4. Fromenty B, Fisch C, Labbe G, Degott C, Deschamps D, Berson A, Letteron P, Pessayre D. Amiodarone inhibits the mitochondrial beta-oxidation of fatty acids and produces microvesicular steatosis of the liver in mice. *J Pharmacol Exp Ther.* 1990;255:1371–1376.

KEY WORDS: acute liver failure ■ dronedarone ■ atrial fibrillation ■ antiarrhythmic